

MODULE 7 L03

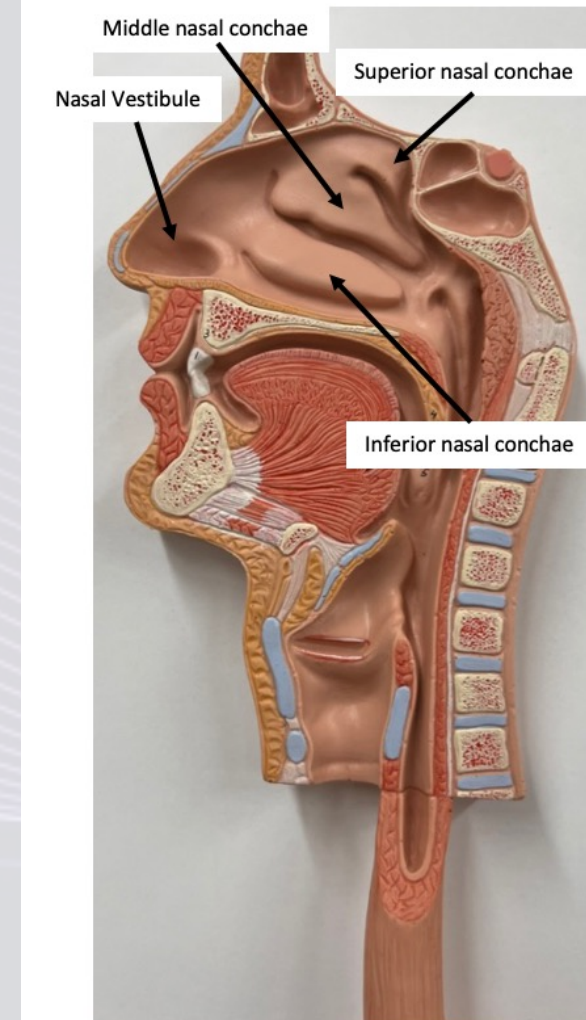
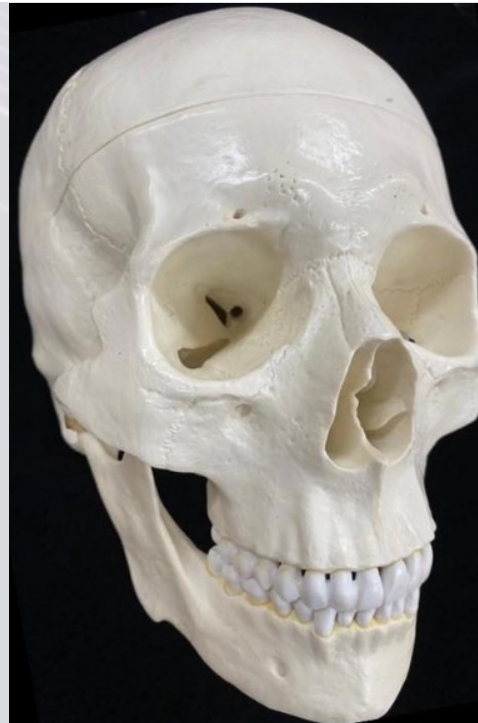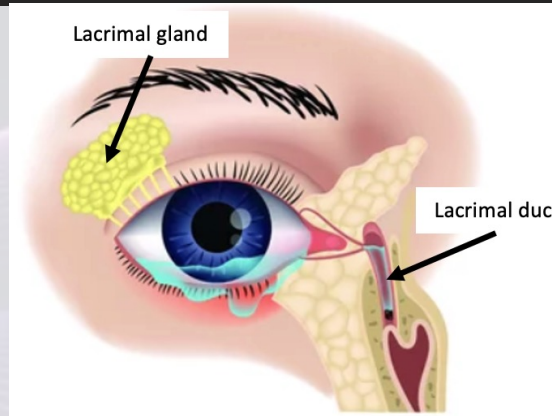
Upper Respiratory Tracts

Dr. Lisa Brinn
lbrinn@fiu.edu



3. Upper Respiratory System

- Nose
- Nasal cavity
- Paranasal sinuses
- Pharynx



Pharynx

1. Nasopharynx
 - Pseudostratified ciliated columnar epithelium
2. Oropharynx
 - Nonkeratinized stratified squamous epithelium
3. Laryngopharynx
 - Nonkeratinized stratified squamous epithelium

